International Journal Dental and Medical Sciences Research (IJDMSR)
ISSN: 2393-073X Volume 1, Issue 5 (Oct- 2017), PP 10-16
www.ijdmsr.com

Ultrasound In Diagnosis of Acute Appendicitis: Its Sensitivity and Specificity

Dr. Tanushree Mondal[1], *Dr. Partha Pratim Mandal[2], Dr. Koushik Dewan[3]
[1](*Assistant Professor, Department of Community Medicine, IPGMER and Assistant Director of Medical Education, Kolkata, India)*
[2] *(Assistant Professor, Department of General Surgery, Malda Medical College, Malda ,West Bengal, India)*
[3]*(Assistant Professor, Department of Laboratory Medicine, School of Topical Medicine, West Bengal, India)*
**Corresponding author: DR. PARTHA PRATIM MANDAL*

Abstract:- The use of radiological studies as diagnostic tools in patients with suspected acute appendicitis has increased recently. In this setting, abdominal ultrasonography is viewed as a possible means in diagnosis of acute appendicitis. This prospective study of patients who suspected to have acute appendicitis was undertaken to determine the sensitivity and specificity of ultrasound in diagnosing acute appendicitis. The radiologist and surgeon were reviewed to identify 118 referrals for abdominal ultrasound between August 2015 and August 2017because of a clinical suspicion of acute appendicitis. Of these cases, 81 proceed to surgery for appendicitis, 77 of them proved to be acute appendicitis intra operatively and histopathological examination. The ultrasound sensitivity, specificity, negative predictive value, and positive predictive value were (57.14%, 945.12%, 54.17%, and 95.65%) respectively. The study concludes a high specificity and lower sensitivity of ultrasound in the diagnosis of acute appendicitis and recommend the use of ultrasound routinely wherever acute appendicitis was suspected.

Keywords:- appendicitis, ultrasound, sensitivity, specificity.

I. INTRODUCTION

Acute appendicitis is one of the most common causes of acute abdominal pain, the most common condition that requires abdominal surgery in childhood, and associated with lawsuits against emergency physicians [(1)]. Acute appendicitis occurs when the appendiceal lumen is obstructed, leading to fluid accumulation, luminal distention, inflammation, and, finally, perforation [(1)]. Classic symptoms of appendicitis are well described, However, up to one third of patients with acute appendicitis have atypical presentations [(2)]. Moreover, patients with alternative abdominal conditions may present with clinical findings indistinguishable from acute appendicitis. Thus, although appendicitis traditionally has been a clinical diagnosis, many patients are found to have normal appendixes at surgery [(3)].

The misdiagnosis of this acute condition has led to the inappropriate removal of a normal appendix in 8–30% of patients. The accuracy of the clinical examination has been reported to range from 71% to 97% and varies greatly depending on the experience of the examiner [(4)]. However, because missed ruptured appendixes have dire consequences, surgeons have traditionally accepted a 20% rate of negative findings at appendectomy and the removal of a normal appendix [(5)]. The rate of negative appendectomy is reported to be between 20% and 30% [(4)]. Imaging methods, such as ultrasonography (US) and computed tomography (CT), aimed at avoiding a misdiagnosis and facilitating earlier surgery, when necessary, have become increasingly important for decreasing the morbidity of the disease [(6)]. Ultrasound findings of acute appendicitis are listed in (table1). Ultrasound criteria to diagnose appendicitis includes the outer diameter of the appendix measures greater than 6 mm. Echogenic inflammatory peri appendiceal fat change. The wall thickness can measure almost 3 mm or greater. progressed appendicitis can demonstrate a gangrenous appendix. The lumen distends tremendously sometime upwards to 2 cm and is not compressible. An appendicolith may be present which will cast an acoustic shadow. A perforated appendix is demonstrated when the appendicular wall has ruptured producing fluid or a newly formed abscess. The appearance is hyperechoic with an echo-poor abscess surrounding the appendix. There may be a reflective omentum around the appendix, a thickened bowel, and enlarged lymph nodes. Asymmetrical wall thickening may indicate perforation. Free fluid in the peri appendiceal region. In order to demonstrate all the possible presentations of appendicitis it is important that the entire appendix is visualized

While 6 mm is usually identified as the cut-off between normal and abnormal appendicular diameter [7]. A value greater than 6 mm is considered to be a sign of acute appendicitis, and a value less than 6 mm is regarded as typical for a normal appendix [8].

II. AIM

The aim of the study is to determine the sensitivity and specificity of sonography in diagnosing acute appendicitis.

III. PATIENTS & METHODS

During the period From August 2015 and August 2017, 118 patients suspected at clinical evaluation of having appendicitis underwent sonographic examination, All patients were clinically examined by the senior surgeon following admission at department of General Surgeryat Malda Madical College Hospital, Malda, West Bengal over a period of 2 years on clinical suspicion for acute appendicitis, The study group included patients aged from 6–52 years (mean age, 25.2 years) consisted of 62 female patients (mean age, 25.8 years; age range 9-48years) and 56 male patients (mean age, 24.5 years; age range6–52 years). All US examinations included in this study were performed by radiologist senior. In each patient, trans abdominal US examination was done. Examinations were performed by a versa pro ultrasound (Siemens ultrasound Systems) using curved array 3 -MHz and linear array 7 - MHz transducers and 7 MHZ curved array. The radiologists used the graded compression technique described by Puylaert.(9)

Follow-Up Procedures: For patients who underwent appendectomy, the sonography findings were compared with the microscopy report as the gold standard for the definitive diagnosis of acute appendicitis (true positive). If the patient did not undergo surgery, the exclusion of acute appendicitis is based on the surgeon's opinion, and laboratory findings. Hence negative US examination of those cases will be considered as a (true negative). Statistical analysis for the data was done to find out the sensitivity, specificity, negative and positive predictive values.

IV. RESULTS

In our study, total 118 patients suspected with clinical evaluation of having appendicitis underwent sonographic examination. All patients were clinically examined by the senior surgeon. Of these cases, 81 proceed to surgery for appendicitis.The study revealed that 77 patients were proved to have acute appendicitis based on microscopical finding (65.25%), while acute appendicitis was excluded in 41 patients according to microscopically or clinical finding (34.75%) as shown in Fig (1). The sonographic criteria of acute appendicitis were true positive in (46 patients), it was false positive in 2 patients only (4.34%) the specificity of the ultrasound finding is (95.12%), the positive predictive value will be (95.65%). The sonographic examination revealed that 72 patients had negative classical findings of acute appendicitis, from those 39 were true negative, while the remaining 33 patient the ultrasound miss the diagnosis of acute appendicitis (false negative). Thus, the sensitivity of the U.S was (57.14%) and the negative predictive value was about (54.17%) (Table 2). In other ward: in 41 patient the appendicitis was excluded either histopathological examination, or according to clinical or radiological bases, from those 39-patient ultrasounds finding for appendicitis was negative. The study clarified that increased appendicular diameter (> 6 mm) and the presence of blind non- comprisable bowelloop was the most frequent sonographic criteria regarding acute appendicitis and found all together seen in 40 patients from the total 46 positive patients about (86.95%). The other finding was of lower frequency. In some patient more than one finding of acute appendicitis was seen by U.S.(table 4)

No normal appendix (diameterr<5mm) was seen in our study. In 40 patient the diameter of the appendix was above 6mm, two patientsonly (5%) have appendicular diameter of (6mm), while the most frequent diameter was 8-10 mm (fig.4) 16 cases (40%). Operation for appendicitis was done in 81patients (68.6%) from the total cases under study. 77 of them (95%) the surgical and microscopical findings showed acute appendicitis, 44 of them (57.14%) have been diagnosed by US. Two cases shown by US not to have acute appendicitis were operated upon basing on clinical suspicion and none ofthem show any feature of appendicitis by microscopy(table 5). Complicated (ruptured appendix) was seen in 17 (22%) patients from those whom appendicitis was proved histopathologically (77 patients). From these ruptured appendices 15 patients (88.23%), inflamed appendix was seen unequivocally by ultrasound.

V. DISCUSSION

The study shows that the specificity and the positive predictive value of ultrasound in the diagnosis of acute appendicitis was significantly high this agrees with most of the authors [8,10,11,12 ,13], while it was disagreed by study done in different centres which shows lower specificity of ultrasound in some centres under study while it wascomparable to our study in other centres[14], but this is exceptional and could be due to variation in sampling or operator experience. Ultrasound was found to be relatively of low sensitivity, and negative

predictive value, this result is multifactorial, the failure to consistently identify a normal appendix on ultrasound is a major factor in the low sensitivity of this modality in our study [15]. Another factor is the intense pain may limit compression and be responsible for false-negative results [13, 16] or it may make graded compression examination impossible altogether [13]. In perforated appendicitis, pain, together with rigidity of the abdominal wall and the presence of distended loops, limits compression, thus reducing sonographic diagnostic sensitivity [17]. The limited ability of sonography to adequately penetrate the abdomen in obese patients has contributed to its lower sensitivity [11]. Nevertheless, this study demonstrated considerable higher sensitivity than west et al who stated that ultrasound sensitivity is about 29%, and much lower sensitivity stated by Claus et al reaching to about (13%) in some centres in a large review done in Austria and Germany. [14] In contrast in some series the sensitivity of the ultrasound was as high as (74%, 85% and 100 %) stated by Diana et al, Jacob J. E and Rettenbacher T.et al [18,11,8]respectively. Interestingly Rettenbacher T. et al found a lower specificity (68%) compared to our study this implies a higher false positive [8]. The study appraise the role of ultrasound not in proving the diagnosis of significant number of the patients but also it was crucial in establishing the diagnosis of many conditions simulating the clinical picture of acute appendicitis as shown in table [3]. In our study the most sensitive finding was the increase the thickness appendix>6mm, this was agreed to thestudy of Kessler N. et al who find that the most specific finding of acute appendicitis is the increase the diameter of the appendix more than 6mm but with a considerable higher rate reaching to about (98%) [10], or reaching to about (100%) as cited by Rettenbacher T. et al[8]. while the less sensitive finding was the abscess, although it was the more specific finding with the appendicolith reaching to about (100%), this was agreed by Franke C. who state that the sensitivity of the abscess and the appendicolith as a sign of appendicitis reaching as low as 2% but with high specificity reaching to about (100%) for both findings, the less specific finding was the presence of the free abdominal fluid, due to its presence in wide list of abdominal problem.[14] In our study, no normal appendix was seen confidently. A non-visualized appendix also presents a major diagnostic difficulty because one cannot confidently exclude appendicitis without examining the appendix. [4] This was agreed by Birnbaum and Wilson [19] who claimed that in their experience and in that of others ([20,21], a normal appendix is visualized in only 0%–4% of cases in the adult population, regardless of the US technique used [10]. On the contrary to our finding Rettenbacher et al [12]who found that normal appendix could be seen in (77%)of cases and the negative predictive value about (100%), whereas Kessler N. et al [10]reported that normal appendix was seen in (73 %) of cases . The diameter of the inflamed appendix in most of the cases in the study was ranging from (8-10mm) this result was statistically significant (P value <0.05), this result was similar to Rettenbacher et al [8]. The frequency of perforated appendix in our study was comparable of that cited by chan I. et al.[4] Tt is worthy to say that sensitivity of ultrasound was significantly high in perforated appendicitis.

VI. CONCLUSION

The ultrasound finding is highly specific in acute appendicitis so it is useful in confirming the clinical diagnosis nevertheless the sensitivity of the ultrasound is relatively low making it unreliable in exclusion.Graded-compression US remains our first-line method in the evaluation of patients referred with clinically suspected acute appendicitis. It can be performed at any time, regardless of specific patient's preparation. The ultrasound is useful in differentiating appendicitis from other acute abdominal condition. We recommend to use ultrasound routinely when acute appendicitis is suspected.It can be performed at any time, regardless of specific patient's preparation.

Table (1): The study parameters of Ultrasound findings in appendicitis

Diameter >6 mm
Blind-ended tubular structure
Non- compressible
Appendicolith
Echogenic mesentery
Free fluid
Abscess
Thickened mesenteric wall

Table (2): specificity and sensitivity of ultrasound in diagnosing acute appendicitis

	+ ve microscopically	-ve microscopically or clinically	Total
+ve sonographically	44 (A)	2 (B)	46
-ve sonographically	33 (C)	39 (D)	72
Total	77	41	118

Specificity (D/D+B) =95.12%Sensitivity (A/A+C) =57.14%
Positive Predictive Value(A/A+B) = 95.65% Negative Predictive Value (D/D+C) = 54.17%

Table (3): Final diagnosis of the patients with negative ultrasound for acute appendicitis

		Frequency (No.)	Percentage
False negative (appendicitis)		33	45.83%
True negative	Normal	21	29.17%
	Right ovarian cyst	14	19.40%
	Ureretric stone	2	2.80%
	Ectopic pregnancy	1	1.4%
	Pelvic inflammatory disease	1	1.4%
Total		72	100%

Table (4): Sensitivity and specificity of the sonographic finding of acute appendicitis

Radiological finding	Frequency	Specificity	Sensitivity
Appendicular diameter (>6mm)	46	94.2%	57.17%
Blind non comprisable loop	46	94.2%	57.17%
Free abdominal fluid	18	91.6%	19.5%
Appendicolith	10	98%	13%
ceacal wall thickening	7	94.2%	9%
Echogenic mesentery	7	94.2%	9%
Abscess in RT iliac fossa	4	100%	5.19%

Table (5): Final microscopical diagnosis post- operatively.

Post-surgicaland Microscopical finding	Frequency	Ultrasound finding
Acute appendicitis	77	Positive in 44 patients
Normal appendix	2	Negative sonographically
Lymphoma	1	Thick bowel loop with 2 L.Node
Forign body in terminal ilium	1	Thick bowel loop , seen ,in RT iliac fossa
Total	81	Operated upon

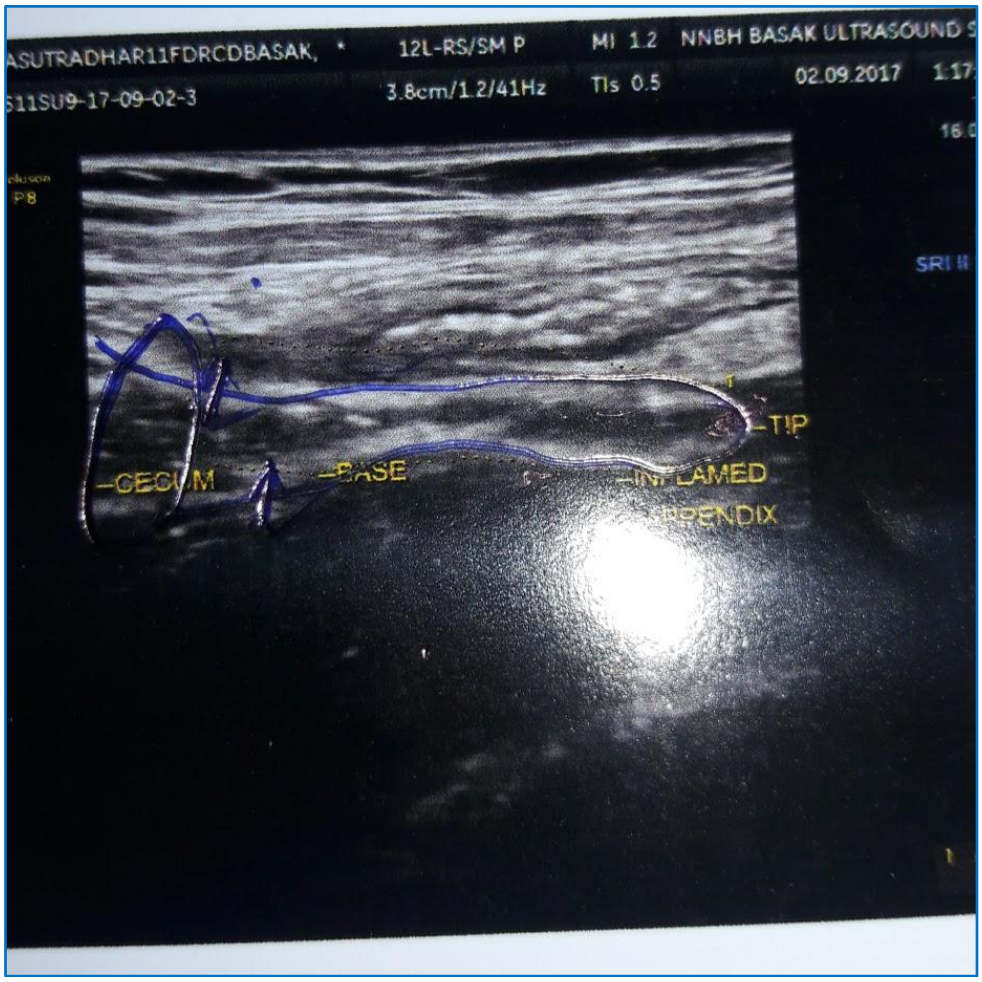

Fig (1): 1 ultrasonographical features of Acute Appendicitis of adult male

Fig (2): 11 year old male with non-compressible appendix of (9 mm) in diameter with echogenic peri-ilial mesentry is seen.

Fig (3): Operative findings of Acute Appendicitis

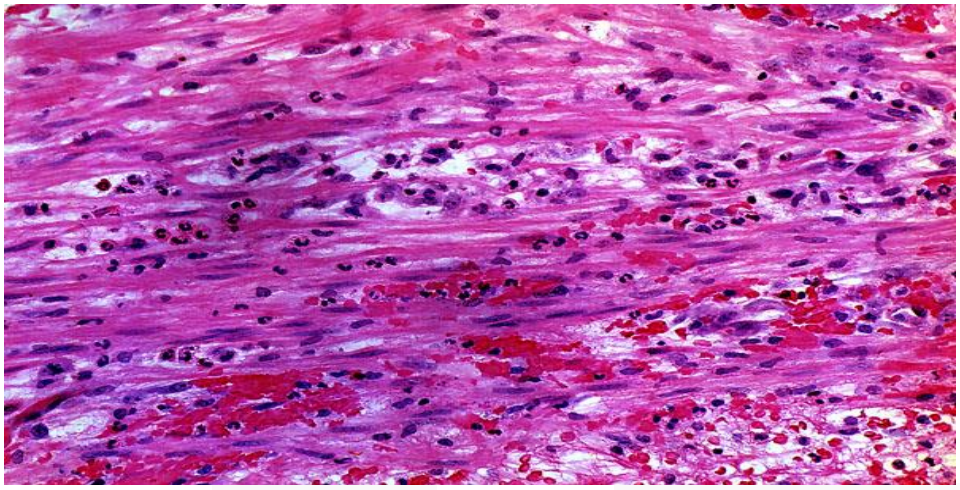

Fig (4): Histopathology of Acute appendicitis. stain. Showing neutrophils in the muscularis propria

REFERENCES

[1]. Leite N P et al. CT Evaluation of Appendicitis and Its Complications: Imaging Techniques and Key Diagnostic Findings. AJR 2005; 185:406-417.

[2]. Lewis FR, Holcroft JW, Boey J, et al. Appendicitis: a critical review of diagnosis and treatment in 1000 cases. Arch Surg 1995; 110:677 – 681.

[3]. Birnbaum BA, Jeffrey RB. CT and sonographic evaluation of acute right lower quadrant abdominal pain. AJR1998; 170:361 –371.

[4]. Chan I, Simon G. Bicknell and Mary Graham. Utility and Diagnostic Accuracy of Sonography in Detecting Appendicitis in a Community Hospital. AJR 2005; 184:1809-1812 .

[5]. Jones PF. Suspected acute appendicitis: trends in management over 30 years. Br J Surg2001; 88:1570 - 1577.

[6]. Andrea S. D. et al. US or CT for Diagnosis of Appendicitis in Children and Adults? A Meta-Analysis. Radiology 2006;241:83- 94.

[7]. John P. McGahan. Can Ultrasound Compete With CT in Evaluation of Possible Appendicitis? ,Applied Radiology, 2002. 31(3):20-28

[8]. Rettenbacher . Outer Diameter of the Vermiform Appendix as a Sign of Acute Appendicitis: Evaluation at US, Radiology ,2001. 218:757-762.

[9]. Puylaert J B. Acute Appendicitis: US Evaluation Using Graded Compression. Radiology 1986; 158:355-360.

[10]. Kessler N. et al Appendicitis: Evaluation of Sensitivity, Specificity, and Predictive Values of US, Doppler US, and Laboratory Findings . Radiology 2004; 230:472- 478.

[11]. Jacobs J.E. CT and Sonography for Suspected Acute Appendicitis: A Commentary, AJR ,2006; 186:1094- 1096

[12]. Rettenbacher T . Ovoid Shape of the Vermiform Appendix: A Criterion to Exclude Acute Appendicitis—Evaluation with US, Radiology ,2003;226:95-100.

[13]. Brooke J.R., Laing F.C, Townsend R.R. Acute Appendicitis: Sonographic Criteria Based on 250 Cases. Radiology 1988; 167:327- 329.

[14]. Franke C. Ultrasonography for Diagnosis of Acute Appendicitis: Results of a ProspectiveMulticenter Trial, World J. Surg. Socie´te´Internationale de Chirurgie 1999 ;23, 141–146.

[15]. Wes w.m. l .Ultrasound and White Blood Cell Counts in Suspected Acute Appendicitis, West Indian Med J 2006; 55 (2): 100.

[16]. Sivit C.J., Newman KD, Boenning DA, et al. Appendicitis: usefulness of US in diagnosis in a pediatric population. Radiology 1992;185:549 -552.

[17]. Baldisserotto M and Edson M, Accuracy of Noncompressive Sonography of Children with Appendicitis According to the Potential Positions of the Appendix , 2000; 175:1387-1392.

[18]. Diana G. Diagnosing Acute Appendicitis in Adults: Accuracy of Color Doppler Sonography and MDCT Compared with Surgery and Clinical Follow-Up, AJR 2008; 190:1300-1306.

[19]. Migraine S, Atri M, Bret PM, Lough JO, Hinchey JE. Spontaneously resolving acute appendicitis: clinical and sonographic documentation. Radiology 1997; 205:55-58.

[20]. Lim HK, Lee WJ, Kim TH, Namgung S, Lee SJ, Lim JH. Appendicitis: usefulness of color Doppler US. Radiology 1996; 201:221-225.

[21]. Incesu L, Coskun A, Bekir Selcuk M, Akan H, Sozubir S, Bernay F. Acute appendicitis: MR imaging and sonographic correlation. AJR Am J Roentgenol 1997; 168:669-674.