International Journal Dental and Medical Sciences Research (IJDMSR)
ISSN: 2393-073X Volume 2, Issue 7 (July- 2018), PP 01-06
www.ijdmsr.com

Auriculo Condylar Syndrome – A Case Report with Differential Diagnosis

Dr. Kamala R[1], Dr. Anu Vijayan[2], Dr. Vical Patel[3], Dr. Brijesh S[4]
[1]*Professor & HOD, Dept.of Oral Medicine & Radiology, Mar Baselios Dental College, Kothamangalam, Kerala, India*
[2]*Assistant Professor, Dept. of Oral Medicine & Radiology, Mar Baselios Dental College, Kothamangalam, Kerala, India*
[3]*Reader, Narsinhbhai Patel Dental College & Hospital, Ahmedabad, Gujarat, India*
[4]*Assistant Professor, Dept. of Orthodontics & Dentofacial orthopaedics, Mar Baselios Dental College, Kothamangalam, Kerala, India*
**Corresponding Author: Dr. Anu Vijayan*

ABSTRACT:- Auriculo-condylar syndrome (ACS) is an autosomal dominant condition with marked phenotypic variability. The condition includes auricular deformity which can vary from auricular cleft, cupped helix to the 'question mark' ear, where there is constriction between the middle and lower thirds of the ear and condylar hypoplasia or aplasia. Other clinical features include facial asymmetry, round facies with prominent cheeks, microstomia, micrognathia,malocclusion and hearing loss. Radiological findings include abnormalities of the the mandibular condyle. The cases reported in the literature are few, may be due to variability in presentation of responsible genes or delayed diagnosis of the condition. The aim of this article is to report a male patient with facial asymmetry, auricular defect and condylar abnormality who is diagnosed as ACS .

Keywords:- Auriculo condylar syndrome, ACS, condylar hypoplasia, question mark ear, micrognathia

I. INTRODUCTION

ACS is a rare genetic disorder of autosomal dominant inheritance. The syndrome was first described by Uuspaa et al in1978[1]. Very few cases with features of this syndrome have been reported in the literature. The hallmark features described are the characteristics appearance of face with micrognathia and abnormal appearance of pinna of ear also known as ‘question mark ear’which was first reported in literature by Cosman et al in 1970[2]. ACS is a syndrome caused by abnormalities that occur during embryonic development of the first and second pharyngeal arches. Wide phenotypic variation is seen in both individual and familial cases of ACS; this may be attributed to varying degrees of gene expression, leading to a range in the severity of clinical signs[3,4,5]. In this case report, we describe a male patient with similar clinical features and diagnostic radiographic manifestations which can add on to the focus of early diagnosis of the condition.

II. CASE REPORT

A 17 year old male patient reported to the department of oral medicine with a chief complaint of irregularly placed front teeth. He was second child of normal and non – consanguineous parents. He was born at term after an uncomplicated pregnancy. Family history was non relevant. All his siblings were normal. No history of trauma or any other systemic diseases were reported. Physical and mental development was uneventful and had no speech and learning difficulties. He was diagnosed with hearing loss of right ear during his childhood by an ENT surgeon.

During Clinical examination a gross facial asymmetry was noted with a sunken cheek on right side and deviated lip towards right side (fig I). Right profile view showed marked micrognathia with flattened body and ascending rami of lower jaw and absence of gonial prominence. Right ear was malformed with decreased size of pinna which was constricted at upper 2/3 and lower 1/3 with elongated ear lobe .Absence of external auditory meatus was well appreciable (fig II a, II b).

Oral examination revealed microstomia, crowding of upper and lower teeth, decreased mouth opening, high arched palate, deviation towards right side with severe malocclusion (fig III).
Hematological values were within normal limits. Radiographic investigations were carried out.

Orthopantomogram (OPG),posteroanterior (PA) skull and lateral skull views showed complete absence of right condyle and coronoid process with a shortened height of ramus (fig IV a, IV b, IV c). Features were further studied by three dimensional cone beam computed tomography (3D CBCT) which showed deviation of lower jaw to right side with aplasia of condyle and coronoid process and absence of external auditory meatus (fig V). Cytogenetic analysis was adviced for the patient, but he was not willing for the same. Orthognathic

surgery along with orthodontic treatment for aesthetic rehabilitation was suggested, but the patient did not turn up for any further treatment.

III. DISCUSSION

The auriculo-condylar syndrome (ACS), first described by Uuspaa[1] in 1978, is recognized as a genetic disorder with autosomal dominant inheritance .The cause of the syndrome based on genetic diagnostic procedure was first mapped to locus on 1p21.1-q23.3[6,4].(Guion-almeida2002, mastti et al 2008). Rieder[7] et al hypothesized that the malformations observed in patients with ACS are due to a homeotic transformation, with the mandible assuming a maxillary phenotype.

The current data suggests that mutations in PLCB4 and GNAI3 account for about 80% of the ACS cases[8]. The genetic defects observed in ACS patients were predicted to result from reduction of EDNRA signaling[8.] When the literature was reviewed there were few cases reported. Uuspaa[1] in 1978 reported a mother and 2 sons with bilateral external ear malformations and hypoplastic mandible. Jampol[3] in 1998 described a family in which several individuals in at least 5 generations had prominent, malformed ears, abnormality of the temporomandibular joint and condyle of the mandible, and microstomia, but normal hearing and normal ossicles of the middle ear. Further cases were reported by Guion[6,9] et al, Storm[10] et al , Nezarati[11] , McGowan[12] et al and Gordon[13] et al.

ACS is characterized by prominent malformed ears with auricular clefts, mandibular condyle aplasia or hypoplasia and several other features secondary to auricular and oral abnormalities. In its most severe form, there is severe micrognathia and a characteristic round facial appearance with prominent cheeks. Most common clinical features reported by Storm[10] et al following a literature review of 14 patients were: abnormalities of TMJ/condyle (100%), ear constriction 96.8%, micrognathia 71%, abnormal palate 62.5%, prominent cheeks 57.1%, microstomia 51.9%, glossoptosis 45.5%, respiratory distress 36.4%, stenotic ear canals 30% and hearing loss21%. Our patient presented with above said features like micrognathia, microstomia, condyle anomaly and hearing loss.

The characteristic congenital auricular cleft malformation in ACS consists of a protuberant cupped pinna with a cleft or notching between the lobule and the helix. This particular ear anomaly is most commonly referred to as ‘‘question mark ear’’ or congenital auricular cleft[10]. Takato[14] et al in 1989 described two siblings and their mother with varying degrees of bilateral ear malformations consistent with congenital auricular clefts. It is possible that these patients have ACS, but because the other characteristic features of ACS were not described, it is impossible to determine whether the features were not present or were present and unrecognized. Complete mandibular condyle agenesis or hypoplasia or more subtle clinical and radiographic anomalies as seen on imaging studies may be present. These findings include micrognathia, short mandibular rami, small coronoid processes, poorly formed TMJs, small condylar necks with anterior placement of the condylar articulations, and increased distances between the external auditory canals and the posterior glenoid fossa[10]. In severe cases of mandibular hypoplasia, glossoptosis leads to upper respiratory tract obstruction. Glossoptosis is also associated with snoring, apnea, and sleep disturbance[10]. No such features of glossoptosis were present in our case. In less severe cases, malocclusion may lead to masticatory abnormalities that require orthodontic treatment or orthognathic surgery which was required in our case. Speech therapy may also be required to treat the articulation defects that have been observed in some patients. Complete intraoral examination and treatment procedures which require intraoral manifestations are not possible with ease in ACS patients due to microstomia and limited mandibular excursions.

The differential diagnosis for ACS includes primarily disorders associated with abnormal development of first and second branchial arch derivatives[15]. They are isolated microtia, Treacher Collins syndrome, Acrofacial dysostoses, hemifacial microsomia and the Goldenhar syndrome.

Treacher Collins Syndrome (TCS), also known as Franceschetti-Zwahlen-Klein Mandibulofacial Dysostosis(MFD1), is a typical autosomal dominant craniofacial disorder with deformities of ears, eyes, cheek bones and mandible.The clinical features comprise down slanting palpebral fissures with lower eyelid coloboma, malar and maxillary hypoplasia with a sunken cheek appearance. Microtia, and other malformations of the ears, and conductive hearing loss due to atresia of the external ear canal can be seen. Cleft palate and absence of the zygomatic arch may occur in severe cases.

Oculo auriculo vertebral spectrum (OAVS), in contrast to TCS, represents a very heterogeneous and complex group of disorders and includes those conditions previously known as hemifacial microsomia and Goldenhar syndrome[16]. Hemifacial microsomia primarily affects the development of ear, mouth and mandible and the anomaly may occur bilaterally. Goldenhar syndrome includes vertebral abnormalities, epibulbar dermoids, upper eyelid colobomas and facial clefts or macrostomia[17,18]. Acrofacial dysostosis is another group of disorders which manifest additional limb abnormalities other than features resembling ACS. It includes Nager syndrome and Miller syndrome. Nager presents with hypoplasia of zygoma, maxila, mandible, downslanting palpebral fissures, absence of the medial lower eyelashes with coloboma of the lower lid, cup-

shaped ears and cleft palate whereas malar hypoplasia, lower lid ectropion, downslanting palpebral fissures, coloboma of the eyelid, micrognathia, cleft lip and/or cleft palate, long philtrum, malformed ears are the characteristic features seen in Miller syndrome. Malformed ears known as 'satyr-ears' are seen in Townes-Brockes syndrome with additional renal and cardiac defects, imperforate anus and triphalangeal thumbs which helps to differentiate it from ACS.

Treatment of these conditions is mainly corrective through surgical interventions. The definitive management includes early identification and characterization of the primary and indirect factors which lead to this group of disorders which will have an important impact on the delineation of the molecular pathways involved in craniofacial development from the first and second pharyngeal arches or even from cranial neural crest cells. Thus it will open new strategies for treatment and rehabilitation of such patients.

IV. FIGURES

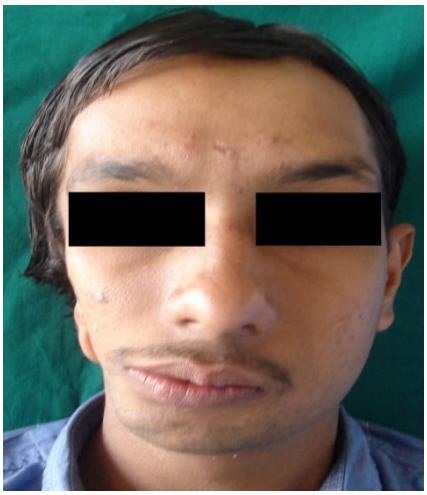

Fig I – extra oral facial view showing facial asymmetry

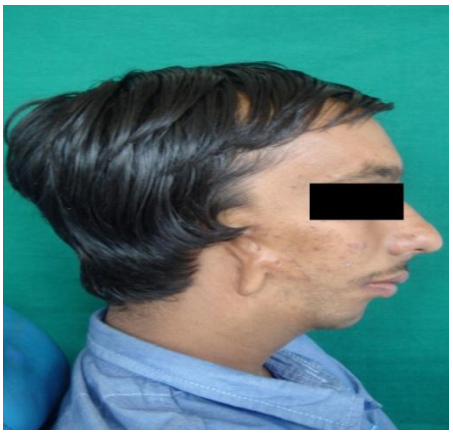

Fig II – right side profile view showing malformed ear and sunken cheeks

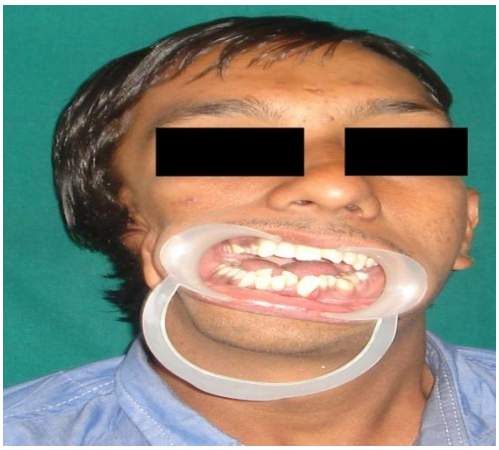

Fig III – intraoral view showing crowded teeth, microstomia and malocclusion with deviation towards right side

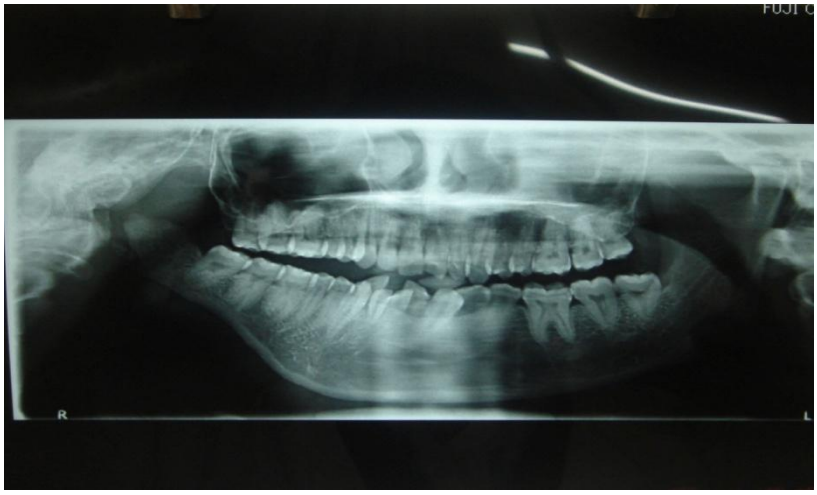

Fig IVa – OPG radiograph

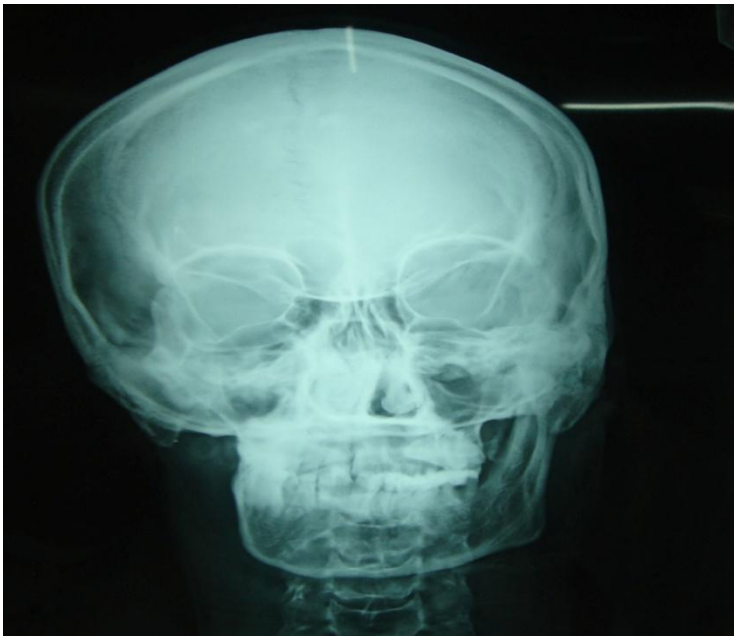

Fig IVb – PA Skull radiographic view

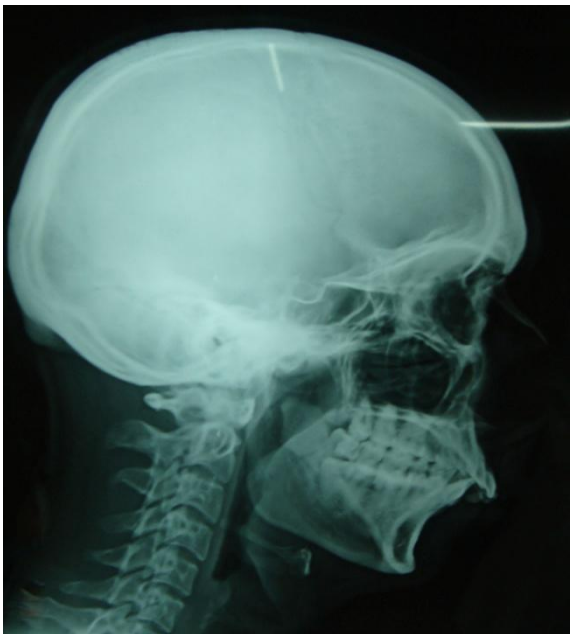

Fig IV c – Lateral Skull radiographic view

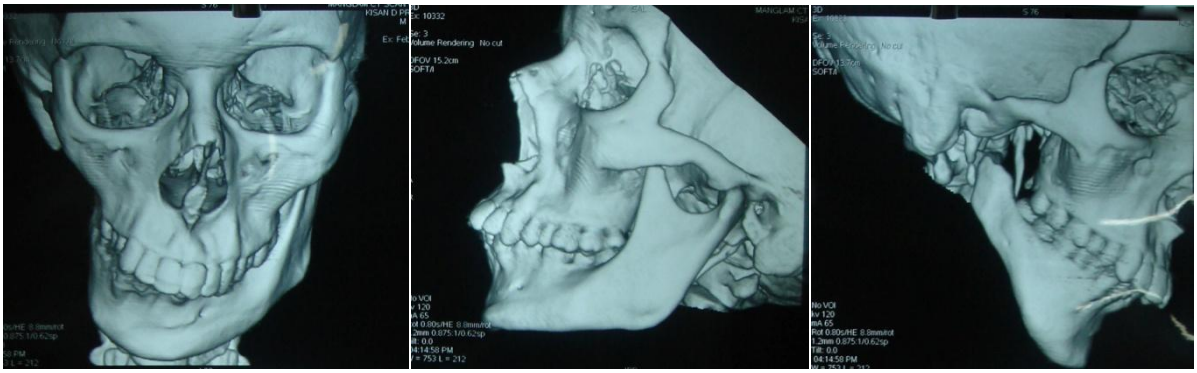

Facial view Left Profile Right Profile

Fig V – 3D Cone Beam Computed Tomography showing facial asymmetry with aplastic right condyle and right coronoid process with intact ramus and condylo-coronoid process on the left side

REFERENCES

[1]. Uuspaa V. Combined bilateral external ear deformity and hypoplastic mandible: case report. Scand J Plast Reconstr Surg. 1978;12:165–67.

[2]. Cosman B, Bellin H, Crikelair GF. The question mark ear. Plast Reconstr Surg. 1970;46:454–57.

[3]. Jampol M, Repetto G, Keith DA, Curtin H, Remensynder J,Holmes LB. New syndrome? Prominent, constricted earswith malformed condyle of the mandible. Am J Med Genet. 1998;75:449–52.

[4]. Masotti C, Oliveira KG, Poerner F, Splendore A, Souza J, Freitas RdaS et al. Auriculo-condylar syndrome: mapping of a first locus and evidence for genetic heterogeneity. Eur J Hum Genet. 2008;16:145–52.

[5]. Passos-Bueno MR, Ornelas CC, Fanganiello RD. Syndromes of the first and second pharyngeal arches: a review. Am J Med Genet A. 2009;149A:1853–59.

[6]. Guion Almeida ML, Zechi Ceide RM, Vendramini S, Kokitsu Nakata NM.. Auriculo condylar syndrome: Additional patients. Am J Med Genet 2002;112:209–14.

[7]. Rieder, M.J., Green GE., Park SS., Stamper BD., Gordon CT., Johnson JM.,et al. A human homeotic transformation resulting from mutations in PLCB4 and GNAI3 causes auriculocondylar syndrome. Am J Hum Genet 2012;90: 907-14,

[8]. Clouthier DE, Passos-Bueno MR, Tavares ALP, Lyonnet S, Amiel J, Gordon CT. Understanding the Basis of Auriculocondylar Syndrome: Insights From Human, Mouse and Zebrafish Genetic Studies. Am J Med Genet C Semin Med Genet 2013; 163C:306–17.
[9]. Guion-Almeida ML., Kokitsu-Nakata NM., Zechi-Ceide RM., Vendramini S. Auriculo-condylar syndrome: further evidence for a new disorder. Am J Med Genet. 1999; 86: 130-33.
[10]. Storm AL., Johnson JM., Lammer E, Green GE., Cunniff, C. Auriculo-condylar syndrome is associated with highly variable ear and mandibular defects in multiple kindreds. Am J Med Genet 2005; 138A: 141-45.
[11]. Nezarati MM., Aftimos S. Microtia, severe micrognathia and absent ossicles: auriculo-condylar syndrome or new entity? Clin Dysmorph 2007; 16: 9-13.
[12]. McGowan R., Murday V, Kinning E, Garcia S, Koppel D, Whiteford M. Novel features in auriculo-condylar syndrome. Clin. Dysmorph. 2011;20: 1-10.
[13]. Gordon CT, Vuillot A, Marlin S, Gerkes E, Henderson A, AlKind, A et al. Heterogeneity of mutational mechanisms and modes of inheritance in auriculocondylar syndrome. J. Med. Genet. 2013;50: 174-186.
[14]. Takato T, Takeda H, Kamei M, Uchiyama K. The question mark ear (congenital auricular cleft): a familial case. Ann Plast Surg. 1989;22:69–73.
[15]. Passos-Bueno MR, Ornelas CC, Fanganiello RD. Syndromes of the first and second pharyngeal arches: A review. Am J Med Genet Part A 2009; 149A:1853–59.
[16]. Gorlin RJ. Branchial arch and oro-acral disorders. In: Gorlin RJCMJ, Hennekam RCM, editors. Syndromes of the Head and Neck. 3rd edition. Oxford: Oxford University Press.2001.pp 790–849.
[17]. Tasse C, Bohringer S, Fischer S, Ludecke HJ, Albrecht B, Horn D et al. Oculo-auriculo-vertebral spectrum (OAVS): Clinical evaluation and severity scoring of 53 patients and proposal for a new classification. Eur J Med Genet 2005;48:397–411.
[18]. Wieczorek D, Ludwig M, Boehringer S, Jongbloet PH, Gillessen-Kaesbach G, Horsthemke B. Reproduction abnormalities and twin pregnancies in parents of sporadic patients with oculo-auriculo-vertebral spectrum/Goldenhar syndrome. Hum Genet 2007; 121:369–76.

Corresponding Author: Dr. Anu Vijayan
[2]Assistant Professor, Dept. of Oral Medicine & Radiology, Mar Baselios Dental College, Kothamangalam, Kerala, India